Original Article

J. St. Marianna Univ.
2024; 15(1): 1−8
doi: 10.17264/stmarieng.15.1

Comparison of Thallium-201 Uptake and Retention Indices for the Evaluation of Glioma Grading

Hisao Nakamura[1*], Masatomo Doi[2], Shouichirou Matsushita[1], So Ode[1], Takahiro Kadoi[3], Hiroko Tagawa[1], Masashi Uchida[4], and Hidefumi Mimura[1]

[1] Department of Radiology, St. Marianna University of Medicine, Kanagawa, Japan
[2] Department of Pathology, St. Marianna University of Medicine, Kanagawa, Japan
[3] Diagnostic Imaging Center of St. Marianna University Hospital, Kanagawa, Japan
[4] Department of Neurosurgery, St. Marianna University of Medicine, Kanagawa, Japan

(Received: June 19, 2023; Revised: October 18, 2023; Accepted: January 4, 2024)

Abstract

Objective: Thallium-201 chloride single-photon emission computed tomography (^{201}TlCl SPECT) has been widely used in brain tumor studies. This study aimed to estimate ^{201}Tl abnormal uptake, frequency of abnormal uptake, and retention indices with ^{201}TlCl SPECT for patients with gliomas.

Materials and Methods: Each patient was intravenously injected with 74—148 Mbq of ^{201}Tl-chloride, and SPECT images were obtained
after 20 min (early imaging) and 4 h (delayed imaging). In the hospital system, 51 patients (54 cases) between January 2015 and August 2019 were enrolled and grouped into three: low-grade glioma (grade II) in 11 patients (12 cases), anaplastic (grade III) in 9 patients (9 cases), and grade IV in 31 patients (33 cases).
Grade classification was classified according to the 2016 World Heath Organization (WHO).
Radiologists placed the region of interest (ROI) on the abnormal uptake on early images, which were drawn on corresponding areas on delayed images. This was evaluated using three different ^{201}Tl uptake and retention indices according to the previous report[1)].
(1) average early ^{201}Tl uptake=Avg.Le/Avg.BRe; (2) ^{201}Tl retention A=Avg.Ld/Avg.Le; and (3) ^{201}Tl retention B=(Avg.Ld/Avg.BRd)/(Avg.Le/Avg.BRe) where Avg.Le is the average count for lesions, Avg.BRe and Avg. BRd are the average early and delayed counts for contralateral normal brains, and Avg.Ld is the average delayed counts for lesions.

Results: Abnormal uptake was seen in 44/55 cases. Grade II were seen in 6/12, Grade III, were seen in 7/9 Grade IV was seen in 30/33. (**Table 2**) The average early ^{201}Tl uptake of grade IV was higher than that of grade II ($P<0.05$), The retention B of grade II was higher than that of grade IV. (**Table 3**)

Conclusion: When there was abnormal uptake, high grade was likely.
In cases with abnormal uptake, if both average early and retention B were high, glioblastoma was considered. If retention B was high, and average early was not, grade II may be considered based on anatomical images.

Key words: ^{201}Tl scintigraphy, glioblastoma, glioma, grading, oligodendroglioma

Introduction

Glioma is the most familiar primary tumor in the brain, accounting for 30%—40% of human central nervous system tumors. The World Health Organization (WHO) suggested classifying gliomas into four

* Address correspondence to Hisao Nakamura, Department of Radiology, St. Marianna University of Medicine, 2−16−1 Sugao, Miyamae-ku, Kawasaki City, Kanagawa 216−8511, Japan
E-mail: hnakamu@marianna-u.ac.jp

grades: grade I and II are low-grade glioma (LGG), while grades III and IV are high-grade glioma (HGG)[2]. There are major differences in their prognosis and treatment. Surgical resection is the recommended treatment for LGGs, while adjuvant radiotherapy and chemotherapy are required for treating HGGs postoperatively[3]. Studies have shown that as the tumor grade is higher, the postoperative recurrence rate is higher, and the survival rate is lower.[4]. Hence, an accurate preoperative grading of gliomas is critical l to guide the selection of treatment and improve the prognosis of patients.

Magnetic resonance imaging (MRI) is considered the important imaging modality for primary work and follow-up of patients with gliomas. Although functional MRI and multiparameter imaging have made tremendous progress in the diagnosis and identification of glioma, their accuracy is still imperfect in judging tumor grading before surgery[5].

Thallium-201 is a mono-valent radioisotope that has biological characteristics similar to potassium.[6, 7] Tl is a potassium analog with high avidity to sodium- and potassium-activated adenosine triphosphatase (Na^+-K^+ ATPase) pump. It was originally developed for myocardial perfusion imaging. ^{201}Tl casually exhibits uptake in lung cancer, liver cancer, and thyroid cancer, and these lesions could be visualized by its uptake[8]. An extraordinary development of research using ^{201}Tl in different tumors took place during the 1990s. It is an excellent radiopharmaceutical for tumor localization, and techniques using^{201}Tl in tumor imaging were modified using single-photon emission computed tomography (SPECT) and various tumor to non-tumor uptake ratios[9, 10]. Its usefulness in the diagnosis of cerebral lesions was also suggested[11]. It was used for intracranial tumor localization[12, 13], tumor grading[1, 14–20], and differentiation of tumor recurrence from radiation necrosis[21].

More recently, with the approval of fluorine-18 fluorodeoxyglucose (FDG) positron emission tomography (PET) for imaging, ^{201}Tl was given up due to the better biological distribution and resolution of FDG. However, FDG-PET is limited by high uptake in a normal brain and low uptake in low-grade tumors, restricting its usefulness in tumor visualization and delineation[22]. FDG PET was not found to be useful regrading to the histologic grade of malignancy compared with 201 Tl scitigraphy[23].

Other PET tracers, such as radio-labeled amino acid and choline-labeled tracers, are being investigated for glioma grading. Some studies showed that ^{11}C-methionine[24] and ^{18}F-fluoro-ethyl-tyrosineare (^{18}F-FET) can differentiate LGG from HGG with high sensitivity and specificity[25].

In Japan, only FDG was approved by health insurance programs, and other PET tracers are not available clinically.

This study aimed to review the clinical usefulness of ^{201}Tl SPECT, which is more easily accessible and cheaper than PET imaging, and to set up the utility of ^{201}Tl scintigraphy again.

Materials and Methods

Image Acquisition

^{201}TlCl SPECT scan was conducted using a three-head rotating gamma camera (GCA-9300A/PI, Canon-Medical Systems, Tokyo Japan) with low energy and super high resolution for beam collimators.

After the intravenous administration of 74–148 MBq Tl, SPECT images were obtained after 20 min (early images) and 4 h (delayed images).

The images were required in a 128×128-pixel matrix in 71 Kev (20% window) photopeaks with 30 steps over 120°at 48-s view.

Reconstruction was achieved with a ramp-filtered FBP method, and a low-pass filter (power factor 80, cut off 0.12 cycles/cm) was used in axial, coronal, and sagittal projections with attenuation and no scanner correction.

The full width at half-maximum of the system was 8.77 mm at the center of rotation when the rotation radius was set to 13.2cm.

Patients and Methods

This retrospective study was conducted under the approval of the institutional review board. It was approved by the clinical study subcommittee of the bioethics committee of St. Marianna University School of Medicine (approval number 4275).

In the hospital information system, 51 patients (54 cases) between January 2015 and August 2019 were enrolled and grouped into three: LGG (grade II) in 11 patients (12 cases: oligodendroglioma, 4 cases; diffuse astrocytoma, 8 cases), anaplastic (grade III) in 9 patients (anaplastic oligodendroglioma, 6 cases; anaplastic astrocytoma, 3 cases), and grade IV in 31 patients (33 cases: glioblastoma). (**Table 1**)

Image Analysis

The ^{201}Tl uptake of tumors was evaluated using qualitative and semiquantitative methods.

Abnormal uptake on early images was judged by

Table 1. Patient Characteristics (n=54) According to the Grade and Histology

Grade	Number of Cases (Histology)
II	12 (OLI 6 and DA 6)
III	9 (AOD 6 and AA 3)
IV	33 (glioblastoma 33)

OLI: oligodendroglioma, DA: diffuse astrocytomoa,
AA: anaplastic astrocytoma, AOD: anaplastic oligodendroglioma

Table 2. Frequency of Abnormal Uptake

Grade	Frequency	Histology
II	6/12 (50.0%)	OLI 2/4(50.0%)and DA 4/8 (50%)
III	7/9 (77.8%)	AOD 5/6 (83.3%) and AA 2/3 (66.7%)
IV	30/33 (90.9%)	glioblasotma 30/33 (90.9%)

Table 3. Index According to the Grade

Grade/Index	Average early	Retension A	Retention B
II	1.92±0.82	1.29±0.27	1.10±0.22
III	3.15±1.88	1.16±0.42	0.85±0.34
IV	3.88 ±1/92	1.04±0.16	0.84±0.16

experienced radiologists (HN and SO) by comparing it with anatomical MRI images visually because there is no physiological accumulation. ROI was placed in a 9—20-mm diameter. The ROI on early images was consistent with that on delayed images.

When there was an abnormal uptake, it was evaluated using three different ^{201}Tl uptake and retention indices according to the previous report[1)]: (1) average early ^{201}Tl uptake=Avg.Le/Avg.BRe; (2) ^{201}Tl retention A = Avg.Ld/Avg.Le; and (3) ^{201}Tl retention B=(Avg.Ld/Av.BRd) / (Avg.Le/Avg.BRe) where Avg. Le is the average count for lesions, Avg.BRe and Avg. BRd are the average early and delayed counts for contralateral normal brains, and Avg.Ld is the average delayed counts for lesions.

Statistics

Chi-square test was used for calculating the frequency of abnormal uptake between different grades. The indices were compared using non-parametric Mann-Whitney U test in JMP[15)].

Differences were considered statistically significant if Probability value (P)<0.05 was considered significant.

Results

1) Frequency of abnormal uptake

Abnormal uptake was seen in 43/54 cases (79.6%). Grade IV was more likely than grade II (P<0.05) (**Table 2**). The histological subtype of grades II and III did not differ. (**Table 2**).

2) Index for abnormal uptake

3) The average early ^{201}Tl uptake of grade IV was higher than that of grade II (P<0.05), while the retention B of grade II was higher than that of grade IV (P<0.05). (**Table 3**)

Illustrative Cases

Case1: 65-year old man with Glioblastoma. On early ^{201}Tl image (**Figure 1-A**), abnormal uptake area is seen in right temporal lobe. On delayed image (**Figure 1-B**), abnormal uptake is also seen (arrow). Average early index is 3.47. Retention index is 1.20. Based on only the ^{201}Tl findings, grade IV is considered.

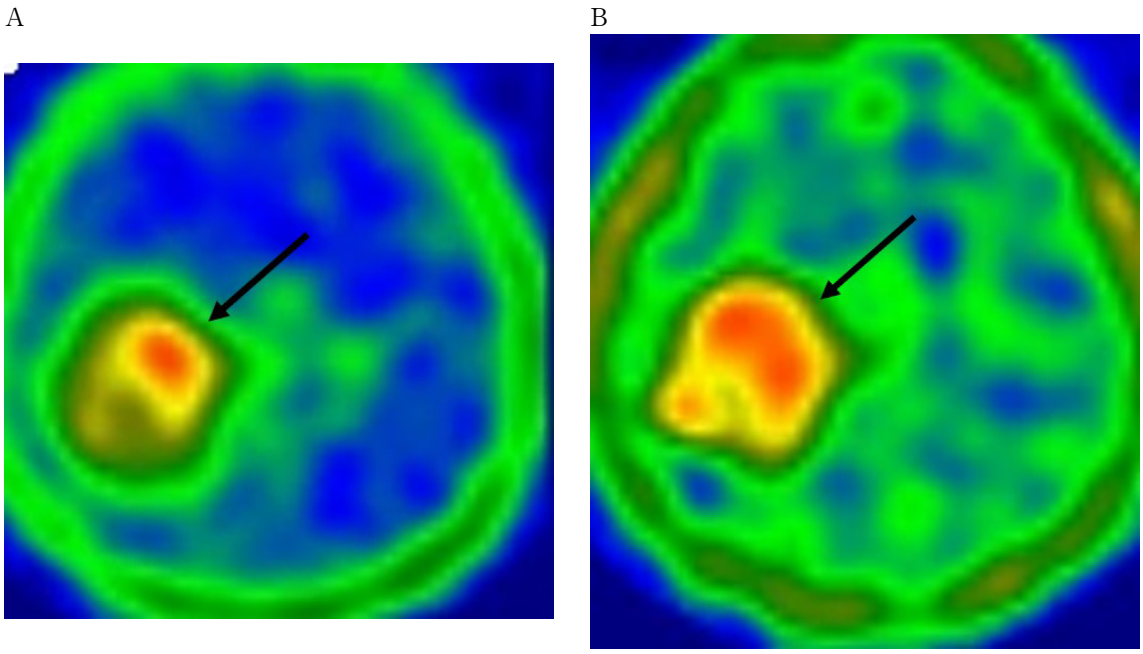

Figure 1. 65-year-old man with glioblastoma
A. Early ^{201}Tl image shows abnormal uptake.
B. Delayed ^{201}Tl image also shows abnormal uptake remains. Glioblastoma is considered.

Case 2: 39-year-old man. Abnormal uptake is seen in left frontal lobe on both ^{201}Tl early (**Figure 2-A**) and delayed phase (**Figure 2-B**). Average early is 2.34, retention index is 0.99. Comparing with Case 1, average early index is not so high. MRI FLAIR image (**Figure 2-C**) shows high intensity mass in the corresponding area. Gadolinium (Gd) image (**Figure 2-D**), ring enhancement is seen. Considering the MRI findings, grade IV is considered.

Case 3: 42-year old man with oligodendroglioma. Early ^{201}Tl image (**Figure 3-A**) shows abnormal uptake (arrow). Delayed ^{201}Tl image (**Figure 3-B**) also shows abnormal uptake. MRI FLAIR image (**Figure 3-C**) and Gd T1 weighted image (**Figure 3-D**) show LGG. However, Average early index is 1.41 and retention index is 0.90, which are consistent with LGG.

Discussion

Grade IV had significantly more abnormal uptake that grade II based on visual assessment. HGG, including grade III, was seen in 37/42 (88.1%). These results were consistent with previous reports, where Sasaki et al. demonstrated 15/16 (93.8%)[23] and Tonami et al. showed 17/17 (100%)[16]. On the other hand, Grade II was seen in 6/12 (50%), while Sasaki et al. and Tonami et al. observed it in 3/7 (42.9%) and 6/9 (66.7%), respectively[16]. Aside from LGG, benign tumors, such as pituitary adenoma and hemangioblastoma, also show abnormal uptake[26, 27]. Hence, the visual evaluation of abnormal uptake may not be useful, but nearly all abnormal uptake seen in HGG gives us a very useful direction. When there is no abnormal uptake, HGG is less likely. Moreover, in a mass or mass-like lesion, in which malignant glioma should be differentiated from benign lesions, such brain abscess or demyelinating disease, HGG is less likely when there is no abnormal uptake on ^{201}Tl scintigraphy.

Secondarily, we will discuss the index when there is abnormal uptake.

In this study, the average early index in grade IV was significantly higher than in grade II. The early Tl density in tumors is connected to tumor vascularity, and vascular permeability is related to the destruction of the blood brain barrier[28].

Glioblastoma is characterized by its high vascularity[29]. As the tumor grows and vascularizes, the vessels get disorganized, dilated, and tortuous[30, 31]. As a consequence, the blood brain barrier increases its permeability and promotes intestinal edema and immune cell invasion[32]. Therefore, the early average

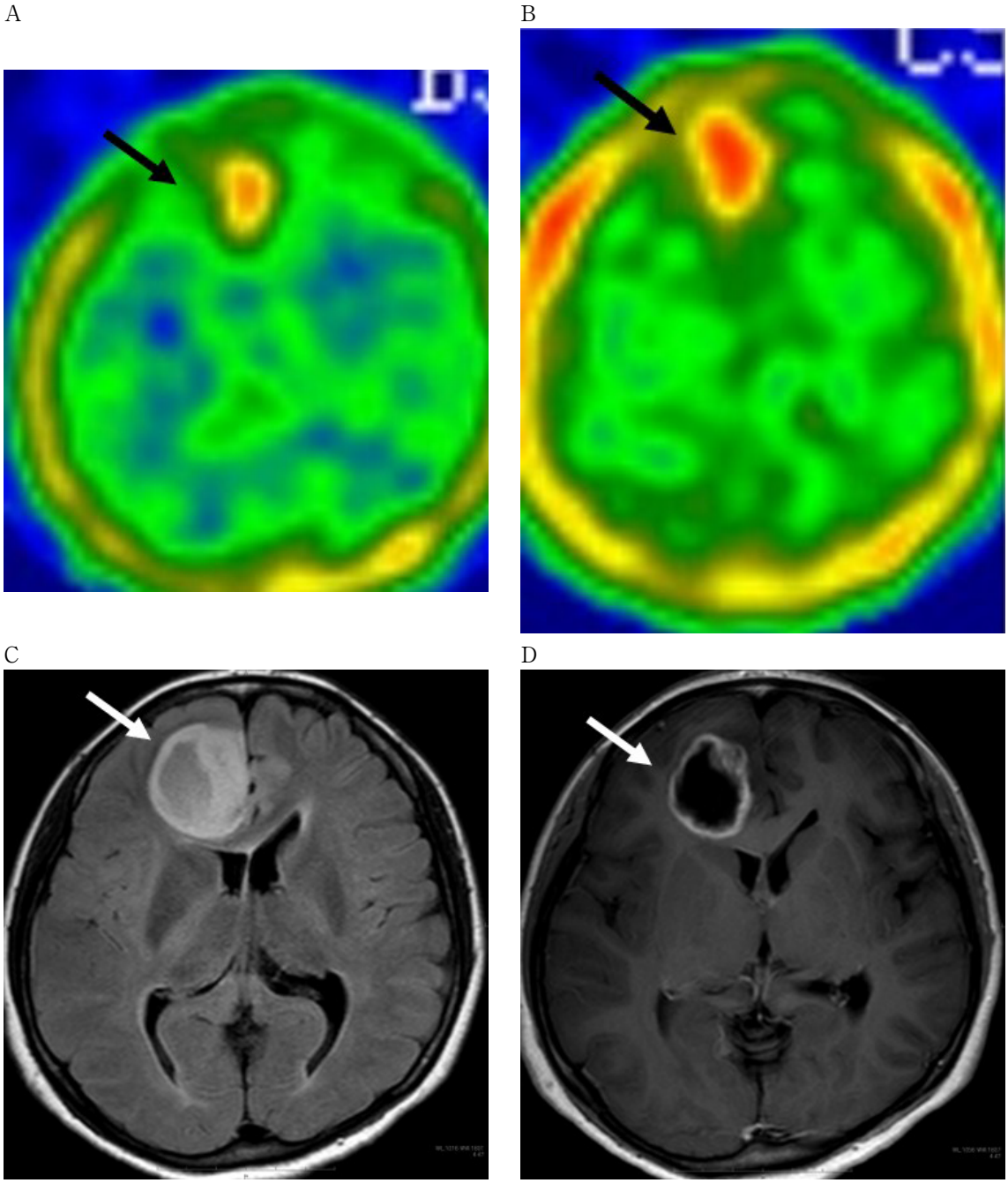

Figure 2. 39-year-old man with glioblastoma

A. Early ^{201}Tl image, abnormal uptake is seen in the left frontal lobe. (arrow)

B. Delayed ^{201}Tl image shows that a strong abnormal uptake remains. (arrow)

C. FLAIR image shows a high-intensity mass in the left frontal lobe, which corresponds to the ^{201}Tl image. (arrow)

D. Gd T1-weighted image shows a ring-enhancing mass. (arrow)

From the MRI image, glioblastoma is considered because of the average early index of 2.34 and retention index B of 0.99, which are consistent with glioblastoma.

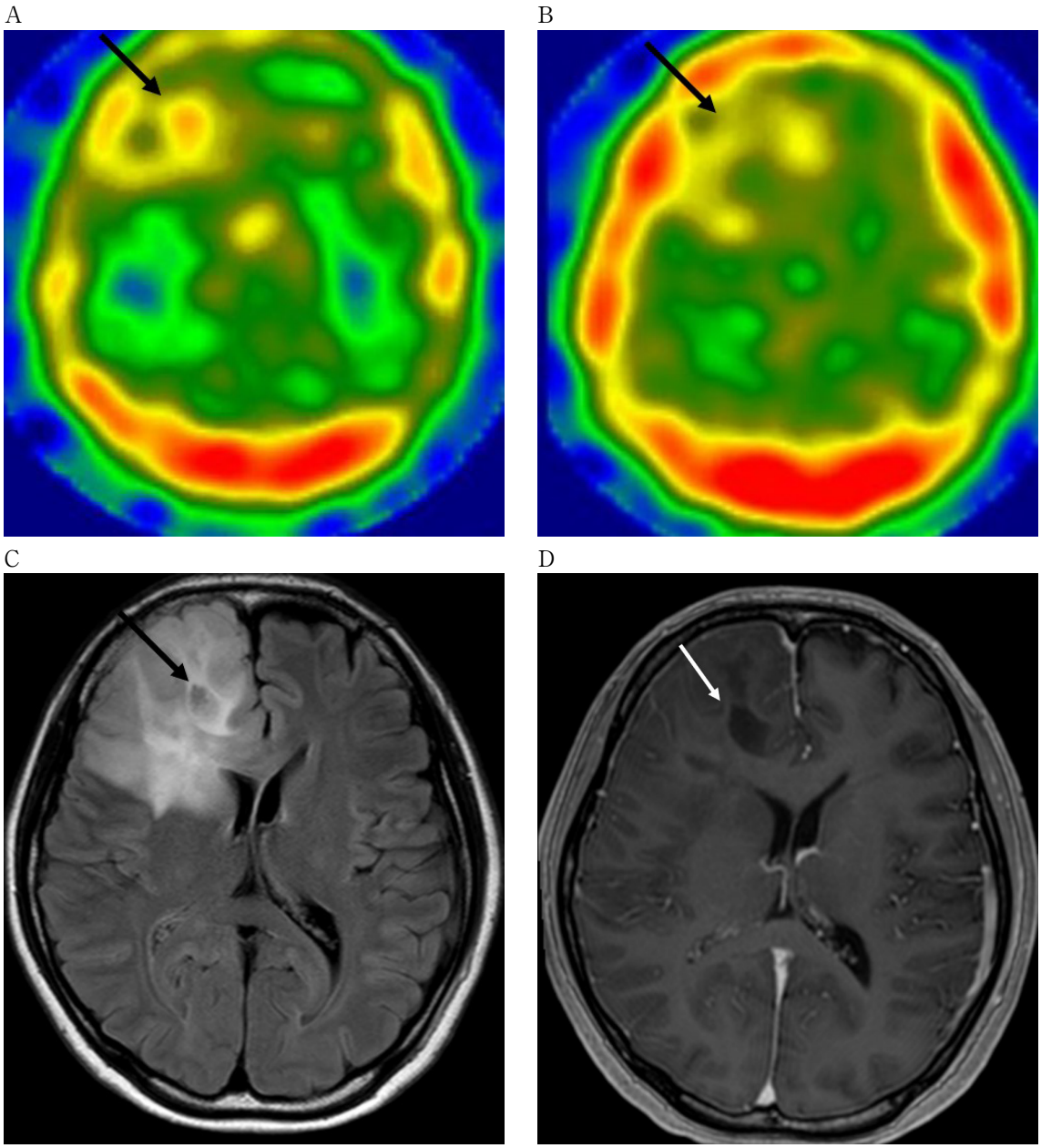

Figure 3. 42-year-old woman with oligodendroglioma

A. Early ^{201}Tl image shows a mild abnormal uptake in the left frontal lobe. (arrow)

B. Delayed Tl ^{201}image shows that a slight abnormal uptake remains. (arrow)

C. FLAIR image shows a low-signal intensity area (arrows) corresponding to the abnormal uptake, from which spread high-signal intensity suggesting edema.

D. Gd T1-weighted image shows no abnormal enhancement.

Based on MRI findings, LGG is suspected. The average early index is 1.41, while the retention index B is 0.90. HGG may be considered because of the retention index, but because the average early is not so high, LGG is compatible with the MRI image.

^{201}Tl was high in grade IV (**Figure 1**).

Finally, on the delayed phase, grade II was significantly higher than grade IV.

When Tl is absorbed into tumor cells by active transport with Na^+-K^+ ATPase, it is reserved in the tumor cells. Previous reports show the retention index suggests the viability of the tumor[33] or correlation with malignancy[17]

In this study, six cases that show abnormal uptake include two oligodendroglioma and four diffuse astrocytoma. Diffuse astrocytoma was diagnosed at that time when oligoastrocytoma disappeared in WHO 2016[2]. We speculated that the higher retention was due to oligocomponents, which are well-vascularized due to a rich network of capillaries and higher cerebral blood volume than conventional diffuse astrocytoma[34, 35]. Hence, we think that once Tl is taken into tumor cells, it is not so easy to be washed out by preventing the rich vascular network. (**Figure 2**)

It is important to note that HGG may be considered with the higher retention, but when the average early index is not high, grade II is more likely, especially with the cortical involvement, which is a characteristic of oligodendroglioma[34].

Therefore, we speculate that on the basis of ^{201}Tl scintigraphy, when retention index shows high value, higher value of average early index suggests glioblastoma.

There are some limitations in this report. First, this was a retrospective study. Moreover, judgment of tracer uptake and ROI placement were based on visual assessment of images. ROIs were operator-dependent. Results obtained with ROIs for abnormal uptake may not represent the character of the entire lesion.

Conclusion

When there is no abnormal uptake on visual assessment, HGG is less likely. In cases with abnormal uptake, the higher average early index may indicate HGG. When the early index is not high and retention index is higher, LGG, such as oligodendroglioma, may be considered by comparing the anatomic images. We want to assert that ^{201}Tl scintigraphy is still useful for glioma grading.

References

1) Katano H, Karasawa K, Sugiyama N, et al. Comparison of thallium-201 uptake and retention indices for evaluation of brain lesions with SPECT. J Clin Neurosci 2002; 9: 653−658.
2) Louis DN, Ohgaki H, Wiestler OD, et al. WHO classification of tumors of the central nervous system, 4th ed, IARC, Lyon, 2016.
3) Le Rhun E, Taillibert S, Chamberlain MC. Anaplastic glioma: current treatment and management. Expert Rev Neurother 2015; 15: 601−620.
4) Ostrom QT, Cioffi G, Gittleman H, et al CBTRUS Statistical Report: Primary Brain and Other Central Nervous System Tumors Diagnosed in the United States in 2012−2016. Neuro Oncol 2019; 21: v1−v100.
5) Zhang L, Yang LQ, Wen L, et al. Noninvasively Evaluating the Grading of Glioma by Multiparametric Magnetic Resonance Imaging. Acad Radiol 2021; 28: e137−e146.
6) Gehring PJ, Hammond PB. The interrelationship between thallium and potassium in animals. J Pharmacol Exp Ther 1967; 155: 187−201.
7) Lebowitz E, Greene MW, Fairchild R, et al. Thallium-201 for medical use. I. J Nucl Med 1975; 16: 151−155.
8) Hisada K, Tonami N, Miyamae T, et al. Clinical evaluation of tumor imaging with 201 TI chloride. Radiology 1978; 129: 497−500.
9) Nadel HR. Thallium-201 for oncological imaging in children. Semin Nucl Med 1993; 23: 243−254.
10) Elgazzar AH, Fernandez-Ulloa M, Silberstein EB. 201Tl as a tumour-localizing agent: current status and future considerations. Nucl Med Commun 1998, 14: 96−103.
11) Kim KT, Black KL, Marciano D, et al. Thallium-201 SPECT imaging of brain tumors: methods and results. J Nucl Med 1990; 31: 965−969.
12) Ancri D, Basset JY, Lonchampt MF, et al. Diagnosis of cerebral lesions by Thallium 201. Radiology 1978; 128: 417−422.
13) Kaplan WD, Takvorian T, Morris JH, et al. Thallium-201 brain tumor imaging: a comparative study with pathologic correlation. J Nucl Med 1987; 28: 47−52.
14) Black KL, Hawkins RA, Kim KT, et al. Use of thallium-201 SPECT to quantitate malignancy grade of gliomas. J Neurosurg 1989; 71: 342−346.
15) Oriuchi N, Tamura M, Shibazaki T, et al. Clinical evaluation of thallium-201 SPECT in supratentorial gliomas: relationship to histologic grade, prognosis and proliferative activities. J Nucl Med 1993; 34: 2085−2089.
16) Tonami N. Thallium-201 SPECT in the evaluation of gliomas. J Nucl Med 1993; 34: 2089−

2090.
17) Ueda T, Kaji Y, Wakisaka S, et al. Time sequential single photon emission computed tomography studies in brain tumour using thallium-201. Eur J Nucl Med 1993; 20: 138−145.
18) Slizofski WJ, Krishna L, Katsetos CD, et al. Thallium imaging for brain tumors with results measured by a semiquantitative index and correlated with histopathology. Cancer 1994; 74: 3190−3197.
19) Ishibashi M, Taguchi A, Sugita Y, et al. Thallium-201 in brain tumors: relationship between tumor cell activity in astrocytic tumor and proliferating cell nuclear antigen. J Nucl Med 1995; 36: 2201−2206.
20) Taki S, Kakuda K, Kakuma K, et al. 201Tl SPET in the differential diagnosis of brain tumours. Nucl Med Commun 1999; 20: 637−645.
21) Schwartz RB, Carvalho PA, Alexander E, 3rd, et al. Radiation necrosis vs high-grade recurrent glioma: differentiation by using dual-isotope SPECT with 201TI and 99mTc-HMPAO. AJNR Am J Neuroradiol 1991, 12: 1187−1192.
22) Chen W, Silverman DH: Advances in evaluation of primary brain tumors. Semin Nucl Med 2008; 38: 240−250.
23) Sasaki M, Kuwabara Y, Yoshida T, et al. A comparative study of thallium-201 SPET, carbon-11 methionine PET and fluorine-18 fluorodeoxyglucose PET for the differentiation of astrocytic tumours. Eur J Nucl Med 1998; 25: 1261−1269.
24) Kato T, Shinoda J, Nakayama N, et al. Metabolic assessment of gliomas using 11C-methionine, [18F] fluorodeoxyglucose, and 11C-choline positron-emission tomography. AJNR Am J Neuroradiol 2008; 29: 1176−1182.
25) Kunz M, Thon N, Eigenbrod S, et al. Hot spots in dynamic (18) FET-PET delineate malignant tumor parts within suspected WHO grade II gliomas. Neuro Oncol 2011; 13: 307−316.
26) Kondo T, Kumabe T, Maruoka S, et al. Diagnostic value of 201Tl-single-photon emission computerized tomography studies in cases of posterior fossa hemangioblastomas. J Neurosurg 2001; 95: 292−297.
27) Nakano T, Asano K, Tanaka M, et al Use of 201Tl SPECT for evaluation of biologic behavior in pituitary adenomas. J Nucl Med 2001; 42: 575−578.
28) Takeda T, Nakano T, Asano K, et al. Usefulness of thallium-201 SPECT in the evaluation of tumor natures in intracranial meningiomas. Neuroradiology 2011; 53: 867−873.
29) Hanahan D, Weinberg RA: The hallmarks of cancer. Cell 2000; 100: 57−70.
30) De Bock K, Cauwenberghs S, Carmeliet P. Vessel abnormalization: another hallmark of cancer? Molecular mechanisms and therapeutic implications. Curr Opin Genet Dev 2011; 21: 73−79.
31) Guyon J, Chapouly C, Andrique L, et al. The Normal and Brain Tumor Vasculature: Morphological and Functional Characteristics and Therapeutic Targeting. Front Physiol 2021; 12: 622615. doi: 10.3389/fphys.2021.622615.
32) Azzi S, Hebda JK, Gavard J. Vascular permeability and drug delivery in cancers. Front Oncol 2013; 3: 211. doi: 10.3389/fonc.2013.00211.
33) Lorberboym M, Baram J, Feibel M, et al. A prospective evaluation of thallium-201 single photon emission computerized tomography for brain tumor burden. Int J Radiat Oncol Biol Phys 1995; 32: 249−254.
34) Cha S, Tihan T, Crawford F, et al. Differentiation of low-grade oligodendrogliomas from low-grade astrocytomas by using quantitative blood-volume measurements derived from dynamic susceptibility contrast-enhanced MR imaging. AJNR Am J Neuroradiol 2005; 26: 266−273.
35) Engelhard HH, Stelea A, Mundt A. Oligodendroglioma and anaplastic oligodendroglioma: clinical features, treatment, and prognosis. Surg Neurol 2003; 60: 443−456.

Financial Support

None

Author contributions

HN conceived and designed the study. MD advised the pathological information, SM, SO and HT analyzed and interpreted the data. TK advised the image information. MU collected the data. HM provided overall guidance throughout the research process. All authors contributed to the drafting and revision of the manuscript and approved the submitted version. All authors take responsibility for the accuracy and completeness of the work and are accountable for addressing any related questions regarding its integrity.

Conflicts of Interest

The authors have nothing to disclose.