

Available online at www.sciencedirect.com

ScienceDirect

journal homepage: www.elsevier.com/locate/radcr

Case Report

A case of emergency stent graft placement for subclavian artery injury during ventriculoperitoneal shunt placement^{☆,☆☆}

Minoru Dote, MD^{*}, Shingo Hamaguchi, MD, Shoko Arizono, MD, Songhyon Cho, MD, Shinji Wada, MD, Shintaro Nawata, MD, Kazuki Hashimoto, MD, Hidefumi Mimura, MD

Department of Diagnostic and Interventional Radiology, St. Marianna University School of Medicine, 2-16-1 Sugao, Miyamae-ku, Kawasaki, Kanagawa 216-8511, Japan

ARTICLE INFO

Article history:

Received 14 October 2024

Revised 29 November 2024

Accepted 6 December 2024

Keywords:

Subclavian artery injury

Stent graft

Ventriculoperitoneal shunt

ABSTRACT

With advancements in medical devices and imaging techniques, endovascular treatment using stent grafts has emerged as a viable and aggressive therapeutic option for traumatic subclavian artery injuries, including iatrogenic cases. Existing literature suggests that endovascular treatment is less invasive and offers hemostatic success rates comparable to traditional surgical methods. However, there is a paucity of case reports, necessitating further investigation into treatment indications and procedural challenges. We report the case of a 50-year-old woman who sustained a right subclavian artery injury during ventriculoperitoneal shunt placement, a rare occurrence of iatrogenic subclavian artery injury. In our approach, we utilized both the right common femoral artery and right radial artery to attempt a pull-through technique, although this was abandoned owing to radial artery spasm. Ultimately, a stent graft was successfully implanted by traversing the injury site with a micro-guidewire via the right common femoral artery. This case highlights the feasibility of endovascular treatment, even in rare injury mechanisms, provided that thorough preoperative and intraoperative imaging evaluations are performed.

© 2024 The Authors. Published by Elsevier Inc. on behalf of University of Washington.

This is an open access article under the CC BY-NC-ND license

(<http://creativecommons.org/licenses/by-nc-nd/4.0/>)

Introduction

Traumatic injuries to the subclavian artery are relatively uncommon, constituting less than 5% of all traumatic artery in-

juries. However, these injuries carry a significant risk of mortality, with rates reported as high as 34.2% [1]. Mechanisms of injury vary and include sharp trauma (56.3%), blunt trauma (21.8%), catheter-related medical interventions (21.3%), and intraoperative injuries (0.6%) [2].

[☆] Competing Interests: The authors declare that they have no known competing financial interests or personal relationships that could have appeared to influence the work reported in this paper.

^{☆☆} Acknowledgments: We thank Phoebe Chi, MD, from Edanz (<https://jp.edanz.com/ac>), for editing a draft of this manuscript.

^{*} Corresponding author.

E-mail address: minoru.dote@marianna-u.ac.jp (M. Dote).

<https://doi.org/10.1016/j.radcr.2024.12.005>

1930-0433/© 2024 The Authors. Published by Elsevier Inc. on behalf of University of Washington. This is an open access article under the CC BY-NC-ND license (<http://creativecommons.org/licenses/by-nc-nd/4.0/>)

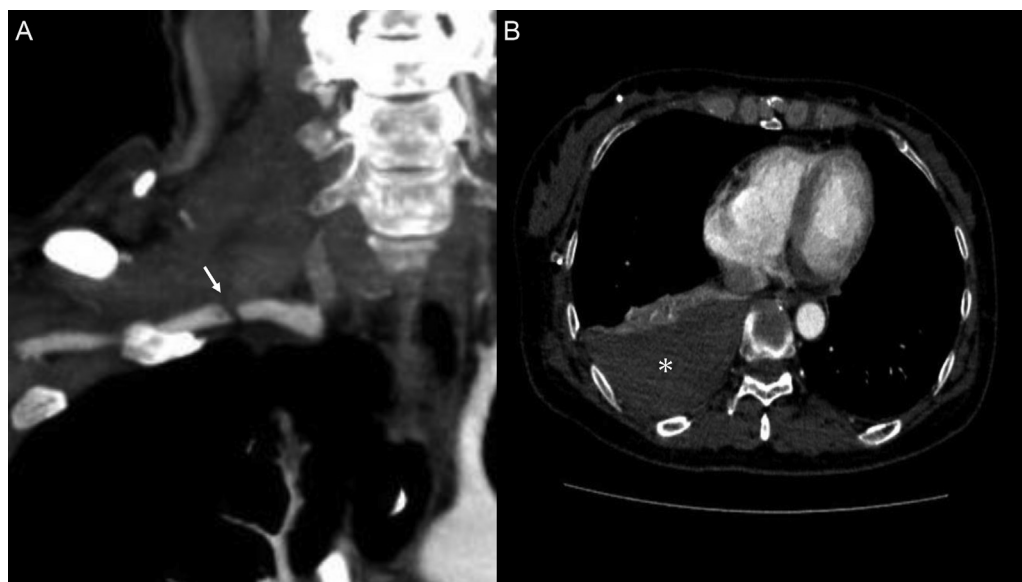


Fig. 1 – Contrast-enhanced chest computed tomography. (A) A partial irregular stenosis and contrast defect in the right subclavian artery (arrow). The normal portion of the right subclavian artery measured 5 mm in diameter. (B) A right hemothorax without extravasation of contrast agent into the thoracic cavity (*). Peripheral blood flow was preserved from the injured area.

Traditionally, surgical intervention has been the standard treatment; however, the anatomical complexity of the subclavian artery and the invasiveness of the surgical approach present substantial challenges. The VIABAHN (W.L. Gore and Associates, Flagstaff, Arizona), consisting of a nitinol stent with an expanded polytetrafluoroethylene (ePTFE) graft lining its lumen, has emerged as an alternative treatment modality. Endovascular treatment using covered stent grafts has been increasingly reported in the context of iatrogenic arterial injuries, including catheter-related trauma [3,4].

Here, we present a rare case of subclavian artery injury caused by a shunt passer during ventriculoperitoneal (VP) shunt surgery, which was successfully treated with a stent graft.

Case report

The patient was a woman in her 50s who developed immediate postoperative shock following ventriculoperitoneal (VP) shunt surgery for hydrocephalus secondary to subarachnoid hemorrhage at an outside facility. Enhanced chest computed tomography (CT) revealed a right subclavian artery injury and a right hemothorax (Fig. 1). It was suspected that the shunt passer may have caused the vascular injury. Blood transfusions and continuous intravenous noradrenaline were initiated. Upon arrival at our institution, the patient's heart rate (HR) was 100 beats per minute, and her blood pressure (BP) was 110/85 mmHg. Hemodynamic parameters remained stable, and CT findings suggested spontaneous hemostasis. However, physical examination revealed diminished pulsations in the right brachial and radial arteries compared with the con-

tralateral side. Following multidisciplinary discussions involving thoracic surgery, vascular surgery, and interventional radiology teams, stent graft placement was planned to prevent rebleeding and late thrombo-occlusive complications.

A 6-French guiding sheath (ASAHI FUBUKI 6Fr; ASAHI-INTECC, Aichi, Japan) was inserted into the brachiocephalic artery via a right common femoral artery approach (Fig. 2A). Prior to stent graft deployment, coil embolization of the dorsal branch of the right subclavian artery was performed using Target XL coils (2 mm × 6 cm and 3 mm × 9 cm; Stryker, Michigan, US) to mitigate the risk of a type II endoleak. The pull-through method, initially considered to guide the stent graft into the right subclavian artery, was abandoned owing to vasospasm during sheath insertion into the right radial artery. Vasospasm was unresponsive to intra-arterial isosorbide dinitrate administration. A 2.0-French catheter (Excelsior 1018, 2.0 Fr, 150 cm; Stryker, California, US) and a 0.016-inch guidewire (SUCCEEDO, 0.016", 180 cm; Boston Scientific, Massachusetts, US) were successfully passed through the injury site from the guiding sheath, which had been advanced via the right common femoral artery approach to the proximal portion of the right subclavian artery. The guidewire was then exchanged for a stiffer wire (V-18 Peripheral Guidewire, 0.018", 300 cm; Boston Scientific, Massachusetts, US) to stabilize the delivery system for the stent graft. The guiding sheath was advanced near the site of the arterial injury. The diameter of the normal segment of the right subclavian artery was measured at 5 mm. Subsequently, a VIABAHN stent graft (6 mm × 5 cm; W. L. Gore & Associates, Delaware, US) was deployed, ensuring that the right vertebral artery remained uncovered. The stent graft was further apposed to the vessel wall using a balloon catheter (Sterling Balloon Dilation Catheter, 6 mm × 4 cm; Boston Scientific, Massachusetts, US). Final angiography

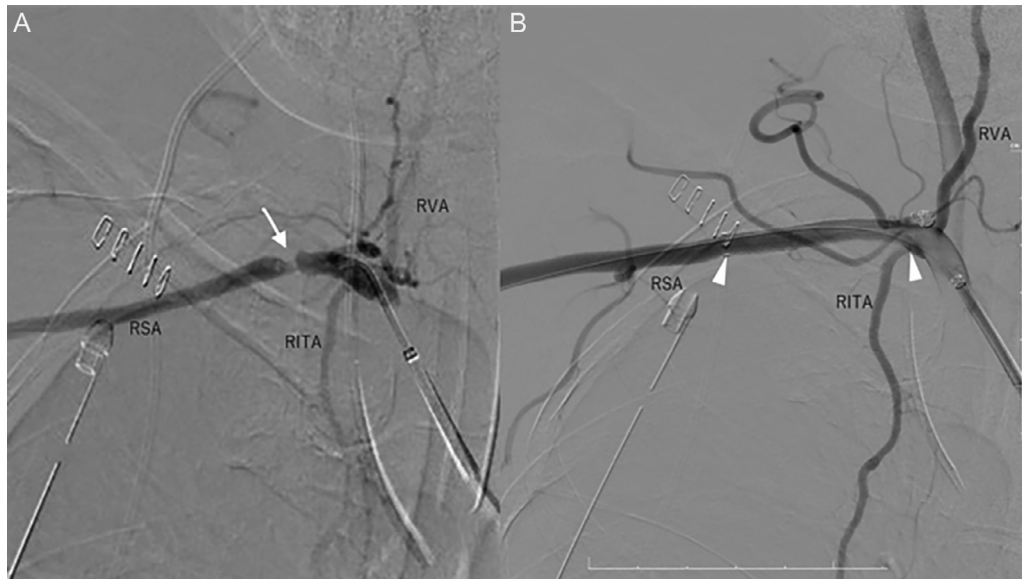


Fig. 2 – Digital subtraction angiography. (A) A 6-F guiding sheath was inserted into the origin of the right subclavian artery via an approach from the right common femoral artery. A partial irregular stenosis and contrast defect in the right subclavian artery are noted (arrow). **(B)** VIABAHN (6 mm/5 cm) was deployed, ensuring it did not cover the right vertebral artery (arrowheads). Angiography confirmed no leakage. RSA, right subclavian artery; RITA, right internal thoracic artery; RVA, right vertebral artery.

demonstrated satisfactory coverage of the injury site (Fig. 2B), completing the procedure.

On the following day, the patient underwent thoracoscopic evacuation of the hemothorax. Because her general condition remained stable postoperatively, she was transferred back to the referring hospital the next day.

Discussion

To date, there have been no documented cases of subclavian artery injury directly caused by shunt passers. The majority of iatrogenic subclavian artery injuries have been attributed to inadvertent arterial puncture during the insertion of central venous catheters or guidewires. Regarding thoracic complications associated with VP shunt placement, Su et al. reported a case of pneumothorax. Their report emphasizes the importance of positioning the tip of the shunt passer upward to prevent pneumothorax by allowing its movement to be monitored from the body surface [5]. The shunt passer typically traverses over the clavicle, but when subclavian artery injury occurs, it is hypothesized that downward pressure may drive the passer into deeper anatomical layers than anticipated. Similarly, the placement of totally implantable central venous access ports via the internal jugular vein, which requires creating a subcutaneous tunnel from the chest to the neck through the supraclavicular area, may pose a comparable risk of arterial injury.

Currently, no consensus exists regarding the optimal management of subclavian artery injuries. However, in recent years, there has been an increasing trend toward endovas-

cular treatment using stent grafts [3,4]. Several comparative reports suggest that endovascular approaches may offer advantages over surgical management. One retrospective study demonstrated that patients treated endovascularly had lower in-hospital mortality and fewer complications compared with those treated surgically, likely owing to the minimally invasive nature of the procedure. Surgical approaches often necessitate more extensive interventions, such as supraclavicular and subclavicular incisions or even median sternotomy, resulting in greater invasiveness [6]. Another retrospective study showed that the endovascular group required fewer total red blood cell transfusions and experienced shorter hospital stays than the surgical group [7]. Endovascular treatment is increasingly favored owing to its reduced invasiveness and associated cost-effectiveness.

The successful deployment of stent grafts in peripheral arteries often requires technical modifications. Given the rigidity of the stent graft, it can be challenging to deliver it to the injury site using the standard over-the-wire technique. The pull-through method has been suggested as an effective solution in such cases [8]. However, in situations where central arterial injuries result in reduced peripheral blood flow, such as in this case, radial artery spasm may preclude the use of this technique. Here, the injured vessel was not significantly tortuous, allowing successful guidewire advancement beyond the lesion via the right common femoral artery. Subclavian artery injury from large devices such as shunt passers should be recognized as a potential complication in this context.

Endovascular repair of subclavian artery injuries using the VIABAHN stent graft presents certain limitations. First, this approach is not suitable for injuries involving avulsion or complete vessel occlusion. Second, a landing zone of at least 2 cm

from the proximal and distal ends of the lesion to healthy vasculature is typically required. Therefore, if the vertebral artery is located near the injury site, the appropriateness of using the VIABAHN device must be carefully assessed. Finally, there are limited long-term data on the use of this stent graft for emergency arterial injuries. Although not specific to arterial trauma, Ohki et al. reported favorable long-term outcomes from a multicenter prospective study using the VIABAHN stent graft for complex SFA lesions in patients with symptomatic peripheral arterial disease. This study demonstrated a 79.1% freedom from target lesion revascularization (fTLR) rate and no occurrences of leg amputation, acute limb ischemia, or stent fractures over a 5-year follow-up period [9]. In terms of emergency arterial injury, Brendel et al. published a retrospective observational study showing a primary patency rate of 92% between 2 and 6 years and a secondary patency rate of 97% between 1 and 6 years [10]. However, it is important to note that this study did not include cases of subclavian artery injury, focusing instead on injuries to abdominal, pelvic, and lower extremity arteries. As such, while evidence supporting the use of stent grafts in peripheral arterial disease is growing, long-term outcomes for subclavian artery injuries remain uncertain. Close monitoring for stent graft occlusion or upper limb ischemia is warranted following treatment of subclavian artery injuries.

In conclusion, although subclavian artery injuries caused by large devices such as shunt passers are rare, endovascular treatment with stent grafts is a viable option provided the injury morphology and vascular anatomy are thoroughly evaluated by imaging. However, because this report is based on a single case, its findings may not be generalizable to other patients or clinical settings. Additionally, the long-term data on the use of VIABAHN stent grafts in this specific anatomical location remain unclear. Large-scale studies involving greater numbers of patients and longer follow-up periods are necessary to more comprehensively evaluate the safety, efficacy, and broader applicability of this approach. Careful follow-up is essential to detect potential complications such as stent graft occlusion or ischemic events in the upper limb.

Patient consent

The authors have obtained written consent from the patient to write and publish this case report.

REFERENCES

- [1] Demetriades D, Chahwan S, Gomez H, Peng R, Velmahos G, Murray J, et al. Penetrating injuries to the subclavian and axillary vessels. *J Am Coll Surg* 1999;188(3):290–5. doi:10.1016/s1072-7515(98)00289-0.
- [2] Dubose J, Rajani R, Gilani R, Arthurs ZA, Morrison JJ, Clouse WD, et al. Endovascular management of axillo-subclavian arterial injury: a review of published experience. *Injury* 2012;43(11):1785–92. doi:10.1016/j.injury.2012.08.028.
- [3] Kuwauchi S, Zempo N, Sakashita H, Uetsuki T, Taniguchi N, Okada T, et al. Use of VIABAHN stent graft for subclavian artery injury due to inadvertent catheter placement. *Jpn J Cardiovasc Surg* 2020;49(2):86–9. doi:10.4326/jjcv.49.86.
- [4] Ben Mrad I, Ben Fatma L, Ben Mrad M, Miri R, Mleyhi S, Mami I, et al. Endovascular management of a subclavian arterial injury during central venous catheter placement for hemodialysis. *Open Access Emerg Med* 2021;13:273–7. doi:10.2147/OAEM.S308233.
- [5] Su TM, Lee TH, Hsu SW. Pneumothorax after a ventriculoperitoneal shunt placement: case report and review of the literature. *Turk Neurosurg* 2020;30(4):621–3. doi:10.5137/1019-5149.JTN.22556-18.1.
- [6] Branco BC, Boutrous ML, DuBose JJ, Leake SS, Charlton-Ouw K, Rhee P, et al. Outcome comparison between open and endovascular management of axillosubclavian arterial injuries. *J Vasc Surg* 2016;63(3):702–9. doi:10.1016/j.jvs.2015.08.117.
- [7] Tanmit P, Angkasith P, Teeratakulpisarn P, Thanapaisal C, Wongkonkitsin N, Prasertcharoensuk S, et al. Treatment outcome of traumatic subclavian artery injuries. *Vasc Health Risk Manag* 2021;16:481–7. doi:10.2147/VHRM.S322127.
- [8] Carrafiello G, Laganà D, Mangini M, Fontana F, Recaldini C, Piacentino F, et al. Percutaneous treatment of traumatic upper-extremity arterial injuries: a single-center experience. *J Vasc Interv Radiol* 2011;22(1):34–9. doi:10.1016/j.jvir.2010.09.015.
- [9] Ohki T, Kichikawa K, Yokoi H, Iida O, Yamaoka T, Maeda K, et al. Long-term results of the Japanese multicenter Viabahn trial of heparin bonded endovascular stent grafts for long and complex lesions in the superficial femoral artery. *J Vasc Surg* 2021;74(6):1958–67. doi:10.1016/j.jvs.2021.05.056.
- [10] Brendel JM, Mangold T, Lescan M, Schmehl J, Ghibes P, Grimm A, et al. Viabahn stent graft for arterial injury management: safety, technical success, and long-term outcome. *CVIR Endovasc* 2024;7(1):23. doi:10.1186/s42155-024-00435-9.